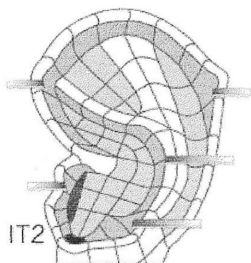
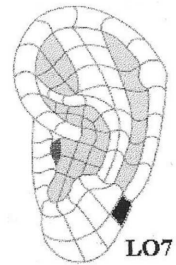
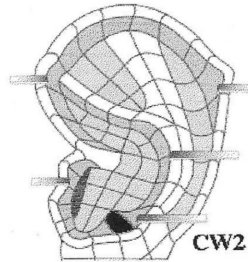
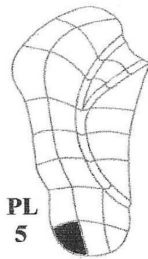
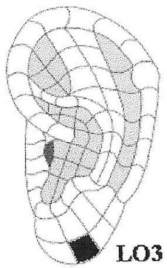
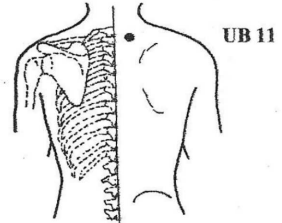
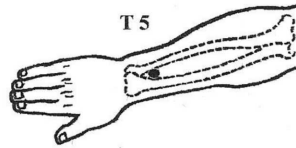
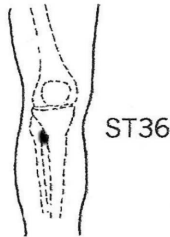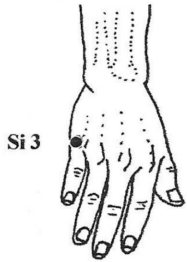
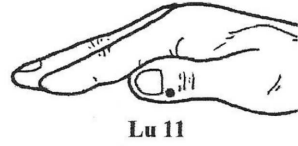
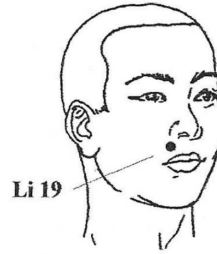
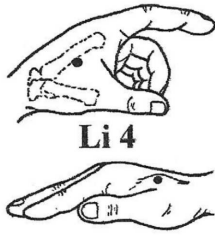
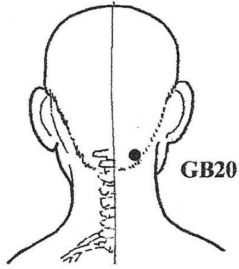


# AcuPoint Analysis MUMPS (PAROTITIS)\*



- GB20** This point is right under and against the base of the skull, in the two small muscular grooves at the back of the neck, two to three inches apart depending on the size of the head.
- LI04** On the back of the hand between the thumb and index finger metacarpal bones. Find the spot midway on the bone that connects the index finger to the wrist. Sometimes this point is easy to find by squeezing two fingers together to form a small mound and marking an imaginary point at the peak of that mound. Then probe inward toward the main body of the hand, right on the bone.
- LI19** The width of one thumb from the face centerline, midway between the nose and the upper lip.
- LU11** 0.1 Cun from the nail bed bottom corner on the top of the thumb. Between the nail and the first joint of the thumb, just behind the nail on the side farthest from the other fingers.
- SI03** On the outer edge of the hand, directly behind the knuckle of the littlest finger.
- ST36** The width of one hand (3 Cun) below the bottom of the kneecap, and the width of one thumb (1 Cun) toward the outside of the leg (direction of the small toe.) Found in the trough or valley where the two most prominent bones of the calf come together.
- T05** The width of two thumbs above the most prominent crease of the upper wrist, in line with the middle finger. On the outside of the forearm.
- UB11** 1.5 Cun from the spine midline, 1 cun below a line level with the top of the shoulder blades. Easily stimulated with the Back-eze.
- ELO03** FACE, CHEEKS, LIPS, TONSIL 4, HELIX 6, PARIETAL LOBE
- EPL05**
- ECW02** THALAMUS POINT, SUBCORTEX (DERMIS), THALAMIC NUCLEI, EXCITEMENT POINT, SALIVARY GLAND
- ELO07** LOWER JAW, MANDIBLE, CHIN, PONS
- EIT02** Endocrine Point, Internal Secretion, Thyrotropins (TSH).